

# PermaFoam<sup>®</sup> Foam Dressing for the Treatment of Problem Wounds

Manfred Zimmermann. Qualified Wound  
Advisor AWM (Academy for Wound Management).  
Paul Hartmann AG, Heidenheim.

## Summary

PermaFoam is a foam wound dressing with properties that make it particularly appropriate for the treatment of chronic ulcerated wounds with aggressive exudate levels .

Case Study 1 presents an ulcer of the ankle of 8 years duration, effectively treated with PermaFoam, allowing resolution with a range of hydroactive dressings.

Case Study 2 presents a chronic amputation wound treated with TenderWet and PermaFoam.

## Introduction

Wound dressings made of foam have become more important for the treatment of chronic wounds. Due to their special characteristics they are indicated above all for the cleansing and conditioning of wounds. One effective foam dressing in clinical practice is PermaFoam whose principles of action and therapeutic benefits are presented here in two case examples

The treatment of chronic wounds with their marked healing impairments is based on two therapeutic approaches: a well-founded causal treatment is indicated for affecting or counteracting the original cause; and proper phase-related wound management is required for local treatment.

For the latter, a number of wound dressing are available which facilitate a specific approach due to their differing physical principles of action. Foam dressings are particularly useful for wound cleansing and conditioning of the wound floor. However, their effectiveness depends on the type of foam used and the construction of the wound pad.

HARTMANN offers a foam dressing that provides a sensible addition to the possibilities for local treatment due to its optimal product design and resulting physical mode of action.



*The basis for the therapeutic effect of PermaFoam is the special pore structure: large pores on the wound side become progressively smaller in the direction of the outer coating layer, which produces a high vertical capillarity. This causes exudates to be quickly drawn up into the body of the foam, but it also ensures high retention for reliable fluid binding.*

## Product structure and principle of action

It is often observed particularly with chronic ulcerations that have existed for a long time that aggressive wound exudate not only hinders the healing process, but also leads to maceration of the wound margins. This maintains the chronicity of the wound because the maceration causes further destruction of tissue and the wound grows larger.

The damaging maceration effect can be prevented with the aid of a wound dressing that is able to quickly and effectively draw the exudate deeply into the absorbent material and reliably hold it there. Technically speaking, foam is an especially suitable material to accomplish these objectives.

The PermaFoam foam dressing is a combination of two differently structured foams that are connected with one another by a special form of lamination. The absorbent layer of PermaFoam consists of hydrophilic polyurethane polymers that can store up to nine times their own weight of liquid in their polymeric chains.

The polyurethane matrix has a unique pore gradient: large pores on the wound side become progressively smaller in the direction of the outer coating layer, which produces strong vertical capillary action.

The outer PermaFoam layer consists of a flexible, closed-porous polyurethane foam and is semipermeable, which means bacteria-proof but permeable to water vapour. This material combination and design results in product characteristics which can counteract the maceration problem.

Via the strongly marked vertical capillarity, the surplus aggressive wound exudate is quickly drawn up to underneath the outer layer.

The large foam pores on the wound side ensure that viscous exudate and detritus are also absorbed without blocking the pores. When absorbing the wound exudate, the polyurethane foam swells slightly, which ensures the contact necessary to draw off discharges from the wound floor.

The absorbed wound exudate then spreads out laterally under the outer layer. In this regard, it is also important that PermaFoam has – mainly due to the special pore structure – a high retention capacity for fluids. Even when pressure is applied from outside by, for example, a pressure bandage, the exudate is retained in the foam.

Also relevant is the fact that the absorptive capacity of PermaFoam is only slightly reduced even under the pressure of a compression bandage. For example, under a pressure of 42 mmHg, the absorptive capacity is reduced by only 12% compared with the pressure-free condition.

Taken together, all of these characteristics result not only in the desirable rapid regulation of exudation, but also protect the wound margins from maceration because the absorbed exudates are not pressed back into the wound again. In addition, the high permeability of the outer layer to water vapour ensures a well-balanced moist microenvironment for the wound, which further supports the healing process.

PermaFoam is atraumatic; sticking to the wound and growth of tissue into the foam structure are minimized. Due to the high absorptive capacity and the very good retention,

PermaFoam can – even with profuse exudation (when no complications exist) – remain on the wound for several days.

PermaFoam is soft and flexible and therefore clings well to the wound contours.

The dressing is held in place with elastic fixation bandages (e.g. Hospifix K) or over the entire area with elastic non-woven fabrics (e.g. Omnifix elastic).

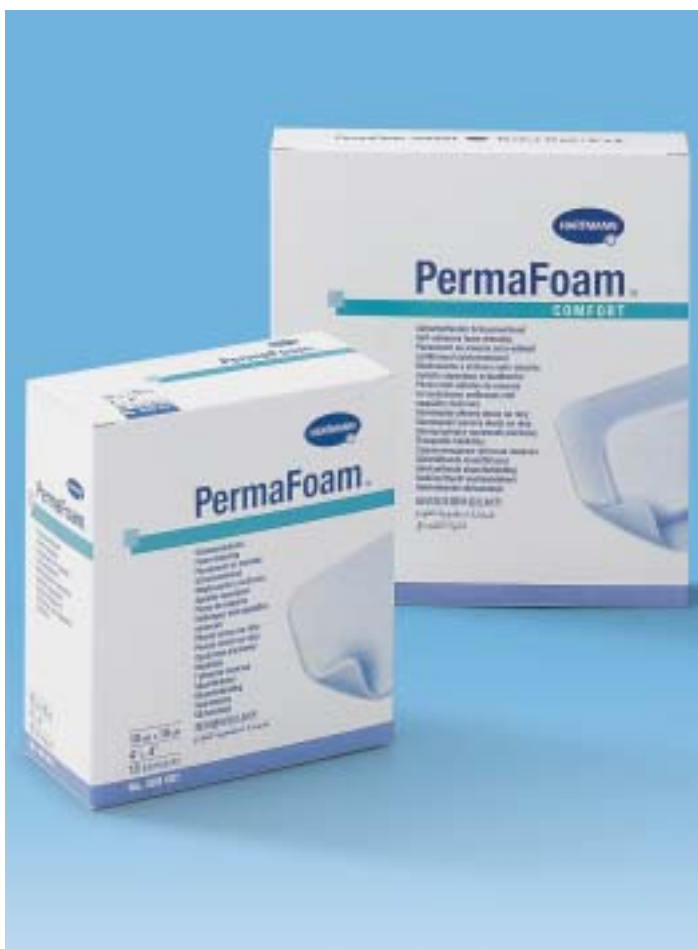For easy fixation, PermaFoam Comfort has a self-adhering adhesive border around the edges, and the polyacrylate adhesive is kind to the skin.

### The indications for PermaFoam:

The foam dressing is suitable for external, heavily to moderately exuding wounds in the cleansing phase and for building up granulation tissue (conditioning).

Areas of application:

- Chronic problem wounds like various types of leg ulcers (noninfected).
- Pressure ulcers (noninfected).
- Burns up to partial thickness.



PermaFoam is available in the following pad sizes: 10 x 10, 10 x 20, 15 x 15 and 20 x 20cm. PermaFoam Comfort with adhesive border is available in the following sizes: 6 x 6, 5 x 14, 10 x 10 and 14 x 14cm.

## Case reports

### Case 1: Venous ulcer

History: Ms. R., 69 years old, suffered from a still not clearly diagnosed ulcer of the ankle as well as decompensated cardiac insufficiency. Due to a degenerative rheumatic disease, she was greatly restricted in her movements and partly dependent on walking aids and a wheelchair. The patient reported that her 'life of suffering' began in the summer of 1996 when she first experienced the following symptoms: swollen, heavy legs, increasing pain in the lower leg, discoloration of the skin (livid discoloration), and itching on the lower leg.

She consulted her family doctor and the result was a treatment with cortisone preparations. This treatment reduced the itching, and the visible external skin color changes also 'faded'. However, other symptoms like increased leg circumference and pain still existed.

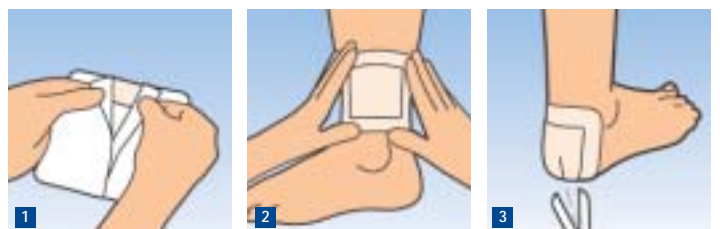In the summer of 1997, on her doctor's orders – and without further diagnostic tests –compression therapy was carried out for the first time (at that time with long stretch compression bandages).

In the fall of 1997, this led to the development of an ankle ulcer that heavily exuded (serous exudate) but only showed a moderate fibrinous coating.

A treatment with enzyme preparations was carried out for 6 months. Under this treatment, there was a slight improvement in the sense of a reduction of the fibrinous coating – however, the wound still existed.

In the spring of 1998, the attending physician decided on a wound treatment with powders and compression therapy. Both measures were continued until the summer of 1999 with negligible improvement. In the fall of 1999, a subinfection of the wound developed.

The patient, who had until then lived at home and taken care of herself (medical care once a week by family physician), was hospitalized. The hospital stay extended from the fall of 1999 to the spring of 2000. The treatment consisted of systemic antibiotic therapy and a local treatment with antiseptics and various other local therapeutic agents.



### The application of PermaFoam Comfort

1. Remove half of the protective paper.
2. Apply the exposed area to the wound; remove the second half of the protective paper; apply PermaFoam to cover the entire wound; press down the adhesive borders. The size of PermaFoam should be chosen so that the absorbent wound pad extends 1-2 cm beyond the wound margins.
3. PermaFoam Comfort (and also PermaFoam) can be cut to size with sterile scissors as needed.

In April 2001, the patient was discharged from the hospital with the diagnosis of *ulcus cruris mixtum*. For the further topical treatment, hydrocolloid dressings were recommended, and these were applied for about a year. The result: the wound floor was clean, but no granulation tissue at all had formed.

In the spring of 2002, the wound became infected again, which again resulted in hospitalization. The patient was treated with systemic antibiotics and local treatment with alginate and silver activated charcoal dressings. Under this treatment, the inflammatory symptoms first declined, and the wound was in the transitional stage between the cleansing phase and granulation phase at the time of hospital discharge.

The patient was not discharged into the care of her family physician with the diagnosis of *ulcus cruris mixtum* this time, but rather with that of *ulcus cruris venosum* (i.e. ankle ulcer). During the further course of treatment up to the end of 2002, the wound healing process came to standstill. This was accompanied by increased fibrin formation.

### Course of treatment as of March 27, 2003

This date marked the beginning of the new therapeutic concept in which the various modes of action of hydroactive wound dressings were used in a phase-related way. After the initial cleansing with TenderWet, PermaFoam was used especially to limit the heavy flow of exudate from the ulcer.

On March 27, 2003, the following wound condition existed: The gravitational ulcer was 4.7 x 4.2 cm (Fig. 1a) and 0.5 cm deep at the deepest place. It was heavily coated with fibrin. The patient had no pain perception on the wound floor.

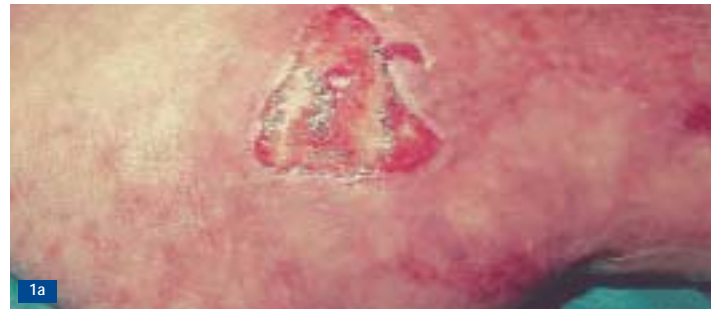There was also a pronounced leg oedema with an oedema of 28cm circumference on the back of the foot. The area directly surrounding the wound showed the infection symptoms of swelling, reddening and hyperthermia. Moreover, there was an ulcer medial above the Achilles tendon that was moderately exuding and had a diameter of 4 cm (this ulcer was treated with Hydrocoll 7.5 x 7.5 cm). On the whole, the skin on the lower leg was dry and scaly.

To achieve a rapid cleansing of the wound as well as a reduction of the symptoms of inflammation, the ulcer on the ankle was initially treated with TenderWet (diameter 5 cm).

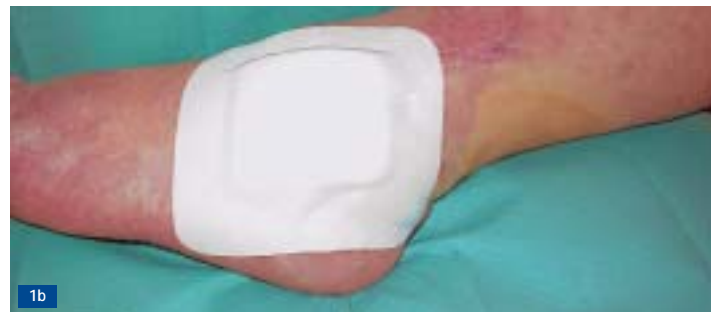The dressing was changed once daily. The TenderWet compress was held in place with a Hospifix K cohesive elastic bandage; additionally, a modified short stretch compression bandage was applied for compression of the leg. The dry skin on the lower leg was treated with Menalind Derm skin care lotion.

These treatment measures were continued for eight days. On April 4, 2003, the wound situation had clearly improved. The fibrinous coating had partly scaled off, and clear islands of granulation tissue were now visible. By this date, the size of the wound had slightly increased to 4.8 x 4.3 cm, but it was now only 0.3 cm deep. Another feature at this time was that the wound was still very heavily discharging serous wound exudate.

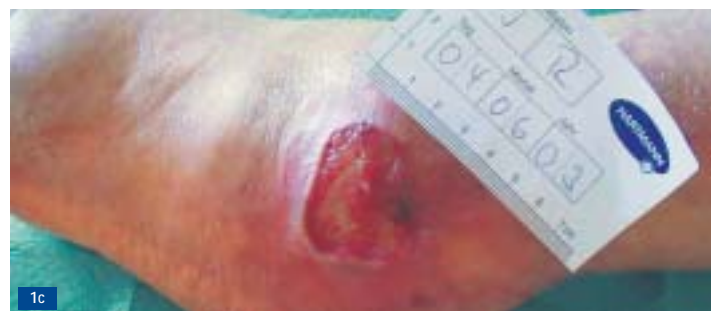
### Case 1: Gravitational ulcer in a 69-year-old female patient that had existed for eight years.



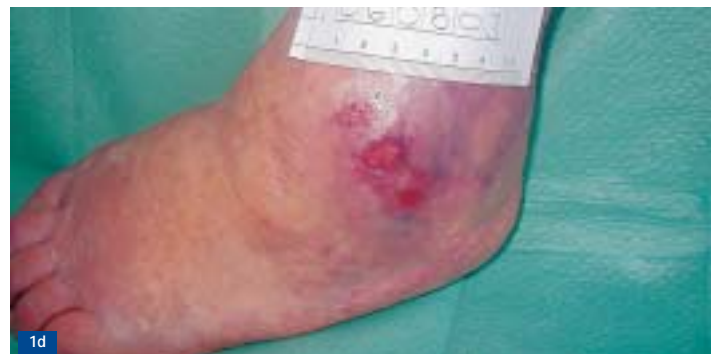*Fig. 1a Condition of the ulcer on March 27, 2003 at the start of applying the new therapeutic approach: local wound treatment with TenderWet to cleanse the wound; compression bandage to counteract the venous insufficiency.*



*Fig. 1b Changeover to treatment with the PermaFoam foam dressing on April 4, 2003 to influence the still heavy flow of exudate and avoid maceration on the wound margins.*



*Fig. 1c Continuation of the PermaFoam treatment until June 2003. Condition of the ulcer on June 4, 2003: the granulation tissue had clearly increased and an epithelial border was clearly visible on the wound margin.*



*Fig. 1d After two further weeks of treatment with PermaFoam, treatment was changed over to Hydrocoll to achieve final wound closure. On August 6, 2003, the wound was closed.*

The area surrounding the wound showed no visible signs of infection! The leg oedema, above all the oedema on the back of the foot, had clearly subsided under the compression therapy (circumference 26cm).