



PAUL HARTMANN LTD
Heywood Distribution Park
Pilsworth Road
Heywood
Lancashire
OL10 2TT
Tel: 01706 363200
Fax: 01706 363201

Web: www.hartmann.co.uk
E-mail: info@uk.hartmann.info



Hartmann Wound Care
Clinical Series No.7

The treatment of problem wounds with Atrauman Ag

Case Study 1:

80 year old patient with post-operative wound complications

Patient of Dr. med. Christoph Bernheim, Munich
(Surgery, Vascular Surgery and Phlebology)

Case Study 2:

74 year old female patient with venous leg ulcer

Patient of Dr. med. Ragnar Storck, Munich
(Skin specialist, Allergology)

In problem wounds, Atrauman Ag, with its bactericide action supports the wound healing process. This is demonstrated by two case studies, a post operative wound and a venous leg ulcer.

The physiological wound healing process can be hindered by various systemic and local factors. The healing of a defective wound by re-building blood vessels, granulation, wound contraction and epithelialisation is only possible when these impeding factors are eliminated.

Case Study 1: 80 year old patient with post-operative wound complications

Patient of Dr. med. Christoph Bernheim, Munich (Surgery, Vascular Surgery and Phlebology)

This 80 year old patient had a post operative wound infection following excision of his 4th toe for Osteomyelitis. He complained of occasional wound pain not severe enough to require analgesic and he was on a course of the antibiotic Amoxicillin. Ten days after operation the wound measured 3.5 x 2cm. Treatment with Atrauman Ag was commenced and 7 weeks later the wound had completely closed.

At the commencement of treatment the wound bed had some coatings and poor granulation tissue present (Photo 3a). There was a small amount of exudate, the wound edges were flat and the peri wound area unremarkable. Atrauman Ag was used in conjunction with PermaFoam. PermaFoam was used as the secondary dressing and initially changed daily.

The most common local impeding factor is infection of the wound (The Surgeon 5; 2004: 471). So that the phases of the wound healing can proceed without disturbance, wound infection should be prevented and diagnosed infection treated effectively. In this instance, Atrauman Ag has proved itself in clinical practice. It is indicated for wounds that are critically colonised or infected. In these cases, Atrauman Ag can be used both as a prophylaxis against infection as well as a supplementary measure to systemic antibiotic

The course of the treatment

According to the doctor treating him, after four days treatment with Atrauman Ag, the infection had abated so the course of antibiotics (Amoxicillin) was stopped.

The condition of the wound continued to improve during the course of the treatment. The proportion of the wound surface covered with coatings continually reduced and the wound began to granulate, epithelial tissue was noted and the wound size decreased.

Two weeks after commencement of treatment the wound bed was clean. 50% each of the wound area was either epithelialised or granulated (Photo 3b). Throughout treatment with Atrauman Ag neither discolouration of the wound nor blockage of exudate were observed. After a total period of treatment of seven weeks the wound was completely reepithelialised and the wound treatment was successfully concluded (Photo 3c).

therapy. Its effective antibacterial action promotes a controlled progress in the woundhealing phases. These two case studies show the effect of Atrauman Ag in promoting wound healing by managing infection.

Assessment by the doctor and patient

The attending doctor stated that he was very satisfied with the result of the therapy. In his view, there had been a marked improvement in the wound following treatment, the defect was completely closed and the treatment was successful. He also noted that the patient had tolerated treatment with Atrauman Ag very well and that it was easy to use.

Conformability to wound bed, ease of removal and antibacterial qualities were all evaluated as good. There were no product residues left in the wound at dressing change.

The patient's evaluation of the treatment with Atrauman Ag was also very positive. Tolerance, wearing comfort and overall impression were evaluated as good. His expectations of his treatment were met.

Case Study 2: 74 year old female patient with venous leg ulcer

Patient of Dr. med. Ragnar Storck, Munich (Skin specialist, Allergology)

A further very interesting case in which Atrauman Ag supported the wound healing process is the treatment of a 74 year old female patient with a venous leg ulcer. The ulcer measured 1.5 x 3.2cm and had persisted for two months. The wound was infected and as part of the treatment, compression bandaging was used to manage the chronic venous insufficiency. The patient was being treated for angina pectoris with appropriate medication (isosorbiddinitrate, amlodipinmesilate, acetylasalicylic acid and L-thyroxin).

Before the commencement of treatment with Atrauman Ag, the wound bed of the ulcer was covered with fibrous coatings (Photo 4a). There was no granulating or epithelial tissue in evidence. There was a small amount of exudate, the wound edges were raised and the peri wound area was reddened. The patient complained of quite severe wound pain.

The wound was treated with Atrauman Ag over a period of 5 weeks. Dressings were changed every 4 - 6 days and PermaFoam was used as the secondary dressing.

The course of the treatment

The wound status had clearly improved after only two weeks of wound treatment. The proportion of coatings was reduced to 30%, and 70% of the wound bed was covered with granulation tissue (Photo 4b). The ulcer continued to exudate during treatment with Atrauman Ag but no impediment to the passage of exudate was noted. The infection cleared and the wound began to heal. Three weeks later saw continuing improvement with increased granulation and the beginnings of epithelialisation (Photo 4c). The peri-wound was healthy and there was no skin discolouration from the silver.

At this time the patient again complained of severe wound pain and due to the improvement in the status of the wound the treatment with Atrauman Ag was discontinued. The attending doctor decided to change over to treatment with hydrogel and alginates combined with Grassolind neutral.

Assessment by the doctor and patient

The doctor stated that the condition of the wound and peri-wound had improved during the treatment with Atrauman Ag, fulfilling his expectations. He also noted excellent wound bed conformability, ease of removal, good patient tolerance and adequate anti bacterial and cleansing action.

The patient confirmed the tolerance already assessed as good by the doctor. The patient thought that the comfort in wearing of Atrauman Ag was good, as was her overall impression. The expectations the patient had set for the therapy were fulfilled.

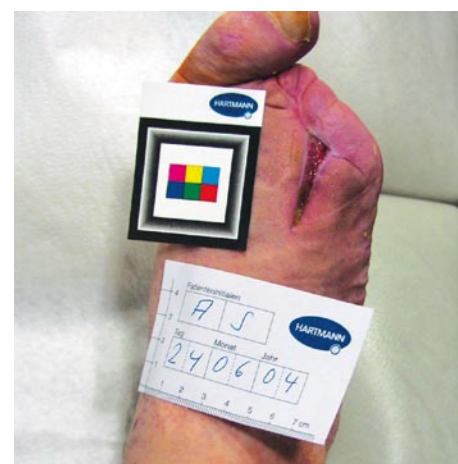


Photo 3a: Initial examination: the wound size is 3.2 x 2 cm, the wound bed is covered with coatings (20%) and with each 40% granulation or epithelial tissue. Treatment with Atrauman Ag in combination with PermaFoam.

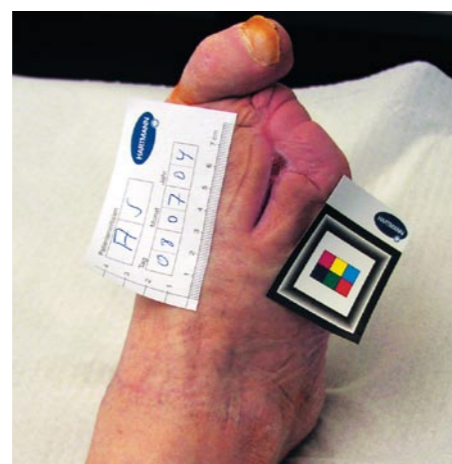


Photo 3b: After three weeks treatment with Atrauman Ag: 50% each of the wound bed is either granulated or epithelialised.




Photo 3c: Concluding examination: complete reepithelialisation following treatment with Atrauman Ag.

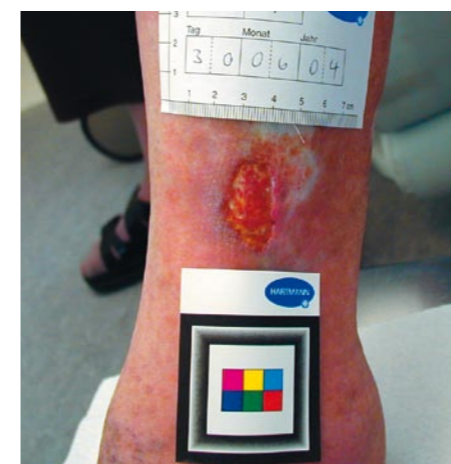

Photo 4a: Initial examination: the ulcer is covered 100% with coatings and infected. Treatment with Atrauman Ag and PermaFoam as well as supplementary compression therapy.

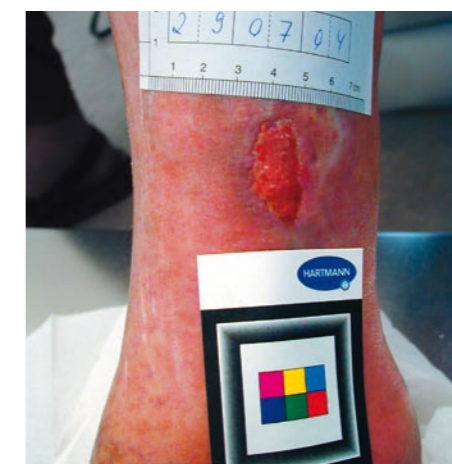

Photo 4b: Dressing change: the proportion of the wound with coatings is reduced to 30%: granulation tissue covers 70% of the wound.

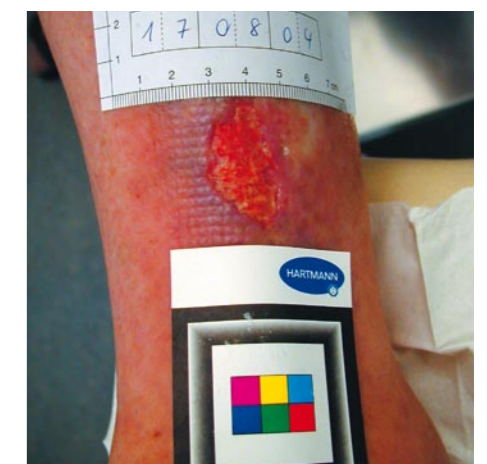

Photo 4c: Concluding examination: 60% of the wound is covered with coatings, 30% has granulation tissue and 10% epithelial tissue. Change over to treatment with hydrogel and alginates combined with Grassolind neutral.